

Mandibular Distraction Osteogenesis in Pierre Robin Sequence: Application of a New Internal Single-Stage Resorbable Device

Fernando D. Burstein, M.D., and Joseph K. Williams, M.D.

Atlanta, Ga.

Pierre Robin sequence may result in physiologically significant obstructive apnea in the neonatal and infant period. This may be life threatening and is most often treated by tracheostomy. To avoid tracheostomy or allow for early decannulation in severely affected infants and children, the authors have developed a new class of neonatal and infant mandibular bone distraction devices. These devices require a single operative procedure for placement and no operative removal is necessary. Fifteen infants (aged 7 days to 11 months; mean age, 3 months) and five children (aged 2 to 8 years; mean age, 5.5 years), 10 boys and 10 girls, with severe obstructive apnea and Pierre Robin sequence were treated with the mandibular infant devices over a 24-month period. Tracheostomy was avoided in 14 patients, whereas five of six patients who had previous tracheostomy were decannulated after mandibular distraction. The final tracheostomy status in one patient will be determined after surgery for gastroesophageal reflux. There were no major complications and no structural device failures. (*Plast. Reconstr. Surg.* 115: 61, 2005.)

Pierre Robin sequence occurs in approximately one in 9000 births.¹ A micrognathic mandible, glossoptosis, and most often a cleft of the palate characterize it. The cause is

thought to be intrauterine pressure on the developing mandible secondary to positioning, frequently associated with oligohydramnios.² There have been some familial cases reported, which may indicate that some cases have an inherited basis.³ A localized intrinsic failure of mandibular growth may be a factor in some cases.⁴ Regardless of the cause, neonates and infants with Pierre Robin sequence may experience varying degrees of airway obstruction and feeding difficulties.^{5,6} The mechanism of the airway obstruction is thought to be the falling back of the tongue into the oral pharynx. Those infants with severe obstruction may suffer from acute hypoxia, exhaustion, and respiratory failure.^{5,6}

Although bone distraction has gained acceptance in children and adults, technical limitations have prevented widespread applications in neonates and infants. Denny and Kalantarjian⁷ and Monasterio et al.⁸ have independently established the feasibility of using external expansion devices in infants with Pierre Robin sequence and severe airway obstruction, with excellent results. These external devices can leave significant scars as the pins track through the skin. In addition, maintaining expander integrity and pin-site hygiene can be challenging. Internal metallic expanders are often too large to fit on the neonatal mandible. Both internal and external metallic expanders require a second operative procedure for removal. We were encouraged by the success of external expansion in neonates and, on the

From the Center for Craniofacial Disorders, Children's Healthcare of Atlanta, and the Division of Plastic and Reconstructive Surgery, Emory University. Received for publication July 30, 2003; revised January 7, 2004.

DOI: 10.1097/01.PRS.0000145794.01442.64

basis of our previous experience with resorbable hardware, embarked on the design and testing of resorbable one-stage expanders.^{9,10} We applied these design concepts to neonates and infants with severe airway obstruction secondary to Pierre Robin sequence.

PATIENTS AND METHODS

Twenty patients (10 boys and 10 girls) underwent bilateral mandibular expansion. Table I lists their clinical features. There were 15 infants aged 7 days to 11 months (mean, 3 months) and five children aged 2 to 8 years (mean, 5.5 years). Six patients had chronic tracheotomies that were placed early in life to relieve severe airway obstruction. In this group, none of the patients tolerated plugging of the tracheostomy, indicating severe upper airway obstruction. Four patients required intubation before distraction because of severe obstructive apnea. All patients met the criteria for Pierre Robin sequence: cleft palate, glossoptosis, and micrognathia. All patients underwent genetics evaluation and five were found to have associated genetic anomalies. Two had Stickler syndrome, one had Opitz syndrome, one had Treacher Collins syndrome, and one had bilateral craniofacial microsomia. Two patients were found to have severe gastroesophageal reflux and one had a complete vascular

ring around the trachea. All had clinical symptoms of severe upper airway obstruction; those that did not have previous tracheotomies required supplemental oxygen, positive-pressure nasal ventilation, or intubation. All patients underwent preoperative team evaluation by an otolaryngologist, a pediatric anesthesiologist, a pediatric intensivist, and a craniofacial surgeon. All of the patients in this series were evaluated by the team and were found to have severe life-threatening airway obstruction secondary to retromicrognathia. The otolaryngologist, whenever feasible, performed a preoperative awake flexible fiberoptic airway examination. Patients who were already intubated underwent direct laryngoscopy and bronchoscopy before distractor placement. Seven patients were deemed to be sufficiently stable to permit preoperative sleep studies.

All patients underwent general anesthesia with nasotracheal intubation. A standard lateral cephalogram and an anterior posterior cephalogram were obtained. The position of the base of the tongue relative to the mandible and oropharyngeal soft tissues and the position of the tooth buds were evaluated from the lateral cephalogram. The optimal distraction vector and osteotomy design were ascertained from this radiographic evaluation. Bilateral incisions 2 cm below the angle of the mandible

TABLE I
Summary of Clinical Presentations and Features in the Study Group with Outcome Data

Age (mo)	Associated Conditions	Predistraction Tracheostomy	Predistraction Intubation	Pre-Low O ₂ Sat% Pre-RDI*	Post-Low O ₂ Sat% Post-RDI*	Comments
48	Stickler	No	No	76	93	
11	Opitz	Yes	No			Tracheostomy
	Gastroesophageal reflux					Pending fundal plication
11	Bilateral Craniofacial microsomia	Yes	No	88	95	Decannulated
3	Vascular ring around trachea	Yes	No	75	98	Decannulated after vascular and tracheal reconstruction
2	Gastroesophageal reflux	Yes	No	65	95	Decannulated after fundal plication
0.3		No	Yes	80	94	
1.2		No	Yes	60	97	
0.5		No	No	73/6.9	98/1.2	
8		No	Yes	83	98	
96	Treacher Collins	No	No	67/8.0	91/.6	
4		No	Yes	65	96	
0.8		No	No	69/26.0	91/.2	
0.8		No	No	78/13.1	91/1	
24		Yes	No	80/9.3	94/.9	
1.8		No	No	78/9.4	92/1.0	
0.3		No	No	79/8.4	92/0	
72		No	No	65/16.5	90/1.9	
3	Stickler	Yes	No	60	93	Decannulated
72		No	No	70	99	
0.8		No	No	85/9.9	95/1.0	

Pre-Low O₂ Sat% Pre-RDI, preoperative lowest oxygen saturation/preoperative respiratory disturbance index; Post-Low O₂ Sat% Post-RDI, postoperative lowest oxygen saturation/postoperative respiratory disturbance index.

* Normal respiratory disturbance index is less than 2.

were carried out after injection of mepivacaine and epinephrine, and scissor dissection below the level of the platysma was performed until the inferior border of the mandible was reached. The marginal mandibular nerve was retracted with the platysma and periosteum. Limited subperiosteal dissection was carried out until enough of the mandible was denuded to place the mandibular infant device. The optimal distraction vector was then marked on the mandible and the drive screw and cable were passed in the same direction (Fig. 1). The distraction screw and cable were placed in the subperiosteal plane and brought through the skin well away from the facial nerve. The distal plates were then threaded onto the drive screw leaving 4 mm between the proximal and distal plates for the osteotomy. The mandibular infant device was then applied using 1.5- or 2-mm bicortical screws, depending on the available bone mass and model of mandibular infant distractor, along the previously marked distraction vector. The metallic drive screw was backed out to the proximal plate and the osteotomy was performed (Fig. 2). Great care was taken to stay monocortical with the reciprocating saw, completing the osteotomy with a 4-mm osteotome to preserve the inferior alveolar nerve. When the osteotomy was completed, the drive screw was threaded into the distal plate housing and the mandibular infant device was activated at least 5 mm to verify the completeness of the osteotomy (Fig. 3). The drive screws were then backed out to bone-to-bone contact and the wounds were closed in




FIG. 2. Application of the distractor to the mandible. The drive screw has been backed out of the distal housing to allow room for monocortical circumferential osteotomy.

layers with resorbable sutures. Patients were maintained sedated and mechanically ventilated in the intensive care unit for the first 5 to 7 postoperative days until the soft-tissue edema had subsided. The team otolaryngologist performed bedside flexible upper airway endoscopy to determine the degree of airway edema and patency while the patient was still intubated. The exact day of extubation was determined on the basis of these findings. Cephalothin was given for 5 days; distraction was started after 48 hours at a rate of 2 mm/day, with extubation at 5 to 7 days. Distraction distances ranged from 15 to 20 mm (mean, 18 mm), determined by the length of the distraction drive screw that was used (Fig. 4).

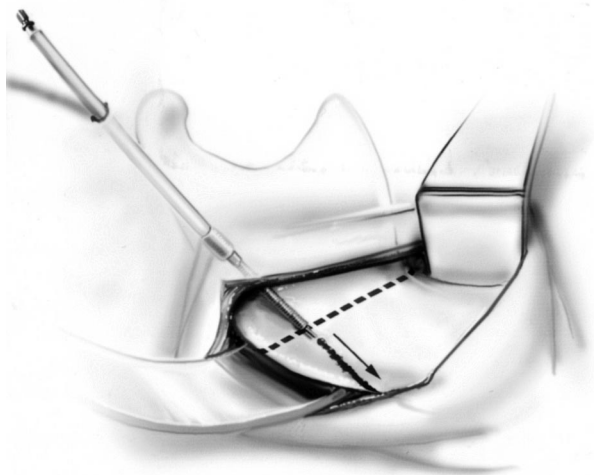


FIG. 1. Exposure of the mandible with determination of the distraction vector and placement of the distraction cable in the direction of the desired distraction vector.

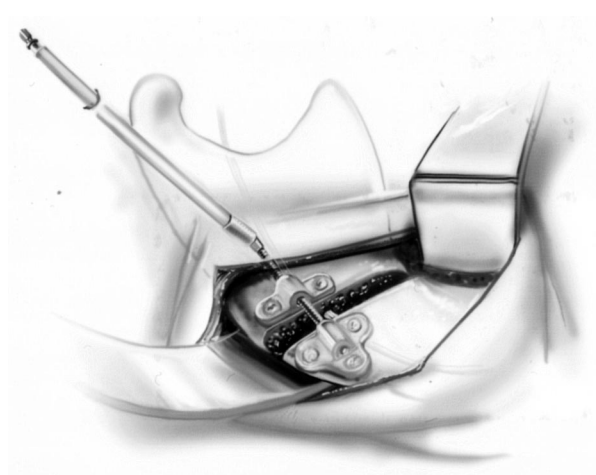


FIG. 3. Activation of the distractor after bilateral osteotomies. Note that the drive screw is fully seated in the distal housing and that osteotomies are complete.

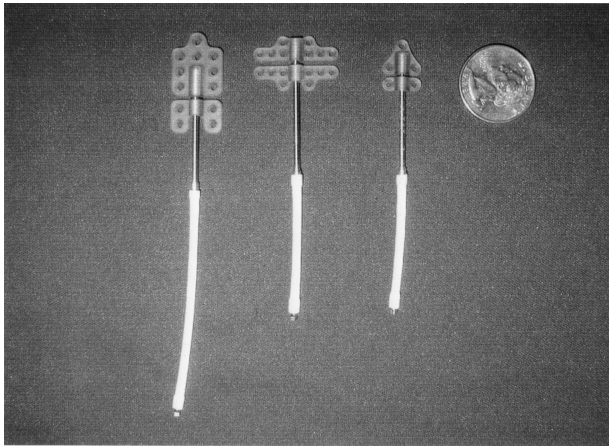


FIG. 4. Mandibular infant distractors, with a quarter to demonstrate scale. Note various sizes and configurations designed for different sizes and shapes of the mandible in infants and children.

After maximal distraction was achieved, 4 weeks was allowed for consolidation. The metallic drive screws were removed in the office without sedation after the consolidation period.

RESULTS

Twenty patients underwent bilateral mandibular distraction. The range of expansion distances was 15 to 20 mm (mean, 18 mm). Table I summarizes the clinical results. There were no major complications. Four patients experienced localized wound infections at the expander cable exit sites. These were treated with local care and oral antibiotics. There were no

structural failures of the mandibular infant devices. There was no clinically noticeable relapse. The maximal distraction, based on the length of the drive screws, was achieved in all cases (Figs. 5 through 7). There were 14 patients who avoided tracheostomy, and five of the six with previously placed tracheotomies were decannulated after mandibular distraction. Two patients failed to improve after distraction of the mandible and required tracheostomy. Postoperative investigation revealed that one of these patients had a vascular ring constricting the trachea and a congenital area of subglottic stenosis. The patient subsequently underwent vascular and tracheal reconstruction and was decannulated. The other patient was found to have severe gastroesophageal reflux, underwent fundal plication, and was subsequently decannulated. One patient who had a tracheostomy before distraction was found to have severe gastroesophageal reflux after distraction and is in the process of being evaluated for fundal plication before attempted decannulation. Nine patients were stable enough to tolerate preoperative sleep studies before distraction. In these patients, preoperative respiratory disturbance index ranged from 26 to 6.9 (mean, 15.34), whereas the postoperative respiratory disturbance index ranged from 1.9 to 0 (mean, 1.11). All distraction screws were removed in the office, without sedation, 4 weeks after completion of the distraction process, without difficulty.

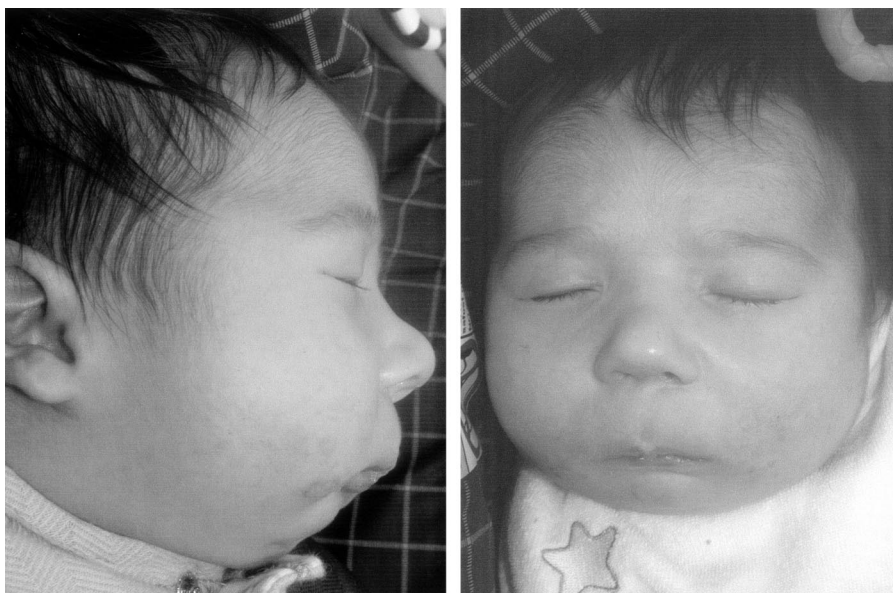

FIG. 5. Preoperative lateral and anteroposterior views of an infant with Pierre Robin sequence and severe obstructive apnea.

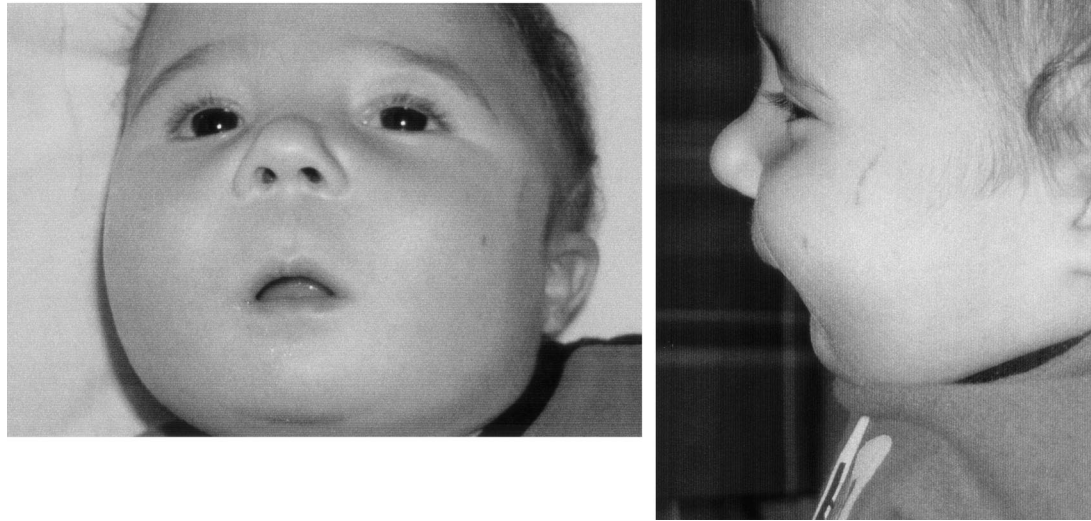


FIG. 6. Postoperative lateral and anteroposterior views of the infant shown in Figure 5 with Pierre Robin sequence 2 months after 18-mm mandibular distraction.

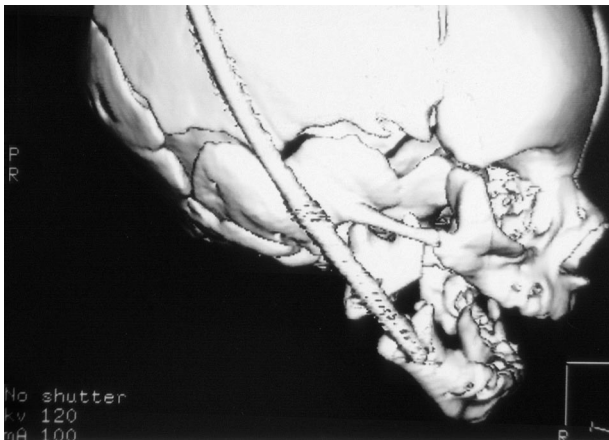

FIG. 7. Three-dimensional computed tomographic scan of the infant taken during the distraction process. The distraction drive screws and cable can be seen. The bone regenerate in the distraction site has not yet calcified and appears as a lucent gap.

DISCUSSION

Pierre Robin sequence occurs in one in 8000 to one in 9000 live births and may be associated with a variety of other malformations.¹⁻⁴ Variable degrees of catchup mandibular growth will eventually occur in most patients, but mandibular dimensions will remain below age-matched norms.¹¹ Immediate supportive measures to ensure adequate ventilation and nutrition will be required in over 70 percent of affected infants.¹²⁻¹⁴ Caouette-Laberge et al. in 1994 proposed a clinical classification to rate the severity of respiratory symptoms: group I,

adequate respiration in prone position and bottle feeding; group II, adequate respiration in prone position but feeding difficulties requiring gavage; and group III, children with respiratory distress requiring respiratory support and gavage.¹⁵ All of the patients we treated fell into group III. Wagner et al. reported non-operative intervention with nasopharyngeal tubes and nutritional support in 22 infants; however, the severity of their respiratory symptoms did not equate to Caouette-Laberge group III.¹⁶ Kirschner et al. reviewed a 28-year experience with tongue lip adhesion in 107 patients with Pierre Robin sequence.¹⁷ Twenty percent of patients who underwent tongue lip adhesion required tracheostomy at a later date. In those patients who required preoperative intubation (group III), more than 40 percent required tracheostomy after tongue lip adhesion. Although it was useful in group II patients, we are concerned regarding the safety and efficacy of tongue lip adhesion in group III patients.

Denny et al. in 2001 demonstrated that mandibular advancement through distraction osteogenesis could improve airway dimensions and result in decannulation in tracheostomy-dependent children.¹⁸ They and Monasterio et al., independently, subsequently reported excellent results using mandibular distraction to prevent the need for tracheostomy in neonates and children with mandibular hypoplasia.^{7,8} Sidman et al. in 2001 reported on 11 children

with severe tongue-based respiratory obstruction secondary to mandibular hypoplasias that were successfully treated by mandibular distraction.¹⁹ Subsequently, there have been others that have successfully treated neonates with distraction of the mandible.^{20,21} All of these authors used external distraction devices. These devices can be difficult to apply to the neonatal mandible, inevitably result in scars as the distraction pins travel through the skin, and can become dislodged or infected during the course of distraction. We previously reported the use of internal titanium devices used to distract the mandible in children.²² Although they were an improvement over external devices, they could only be applied to children with a relatively developed mandible (3 to 5 years old) because of the width of the device. In addition, these devices required operative removal after consolidation of the bone regenerate, which added time, morbidity, and cost to the distraction process. Recently, we reported on a new class of devices that combined the features of an internal distraction device with resorbable plates and screws made from LactoSorb (Walter Lorenz, Inc., Jacksonville, Fla.) to allow for single-stage distraction.¹⁰ Among these new devices are the mandibular infant devices that are small enough for application to neonatal distraction. Three distinct designs allow the surgeon to select the model that best suits the anatomical parameters of the patient's mandible, angle of distraction, and bone mass (Fig. 4). The small dimensions allow application to even the neonatal mandible. The proximal and distal plates can be thermally contoured to precisely fit the mandible. The small external incisions provide excellent visualization of the mandible, allowing for preservation of the inferior alveolar nerve, and have healed without need for revision in all cases. Placement of the distraction vector and subsequent osteotomy in a slightly oblique orientation (Fig. 1) provides maximal tongue base advancement from the posterior oropharyngeal wall.⁷ In addition, this avoids the tooth follicles. Our technique for intraoperative application and activation can be performed in less than an hour, without need for blood transfusion, and allows for precise placement of the devices. Our previous experience with the use of resorbable plates in surgery for craniosynostosis gave us confidence that the same material would have adequate mechanical strength for distraction applications.⁹ There

were no mechanical failures in the present series of mandibular distractions. The drive screw and extension cable have been easily removed in the office setting in all cases without need for a second procedure. This series of patients with grade III symptoms was treated with a 95 percent success rate with single-stage distraction using the mandibular infant resorbable device class. The two initial failures were attributable to a rare lower airway abnormality in one case and severe gastroesophageal reflux in the other. These two patients were subsequently decannulated after surgical correction of these problems. One patient awaits surgery for gastroesophageal reflux before attempted decannulation.

Our experience confirms the findings of Denny and Kalantarian,⁷ Monasterio et al.,⁸ and Denny et al.¹⁸ Mandibular distraction is a safe and effective technique with which to relieve upper airway obstruction in infants and children with Pierre Robin sequence. These devices represent the evolution of mandibular distraction for mandibular hypoplasia in Pierre Robin sequence. We hope that in the future, single-stage distraction osteogenesis of the mandible rather than tracheostomy becomes the first choice in treatment of patients with Pierre Robin sequence and life-threatening upper airway obstruction.

Fernando D. Burstein, M.D.
Suite 500
975 Johnson Ferry Road
Atlanta, Ga. 30342
fburstein@atlplastic.com

REFERENCES

1. St-Hilaire, H., and Buchbinder, D. Maxillofacial pathology and management of Pierre Robin sequence. *Otolaryngol. Clin. North Am.* 33: 1241, 2000.
2. Randall, P., Krogman, W., and Jashina, S. Mandibular growth in Pierre Robin syndrome. In *Transactions of the Third International Congress of Plastic Surgery*. Amsterdam: Excerpta Medica, 1964. Pp. 294-296.
3. Fraser, G. R., and Calnan, J. S. Cleft lip and palate: Seasonal incidence, birth weight, birth rank, sex, site associated malformations and parental age. A statistical survey. *Arch. Dis. Child.* 36: 430, 1961.
4. Pruzansky, S., and Richmond, J. B. Growth of the mandible in infants with micrognathia: Clinical implications. *Am. J. Dis. Child.* 88: 29, 1954.
5. Robin, P. Backward lowering of the root of the tongue causing respiratory disturbances. *Bull. Acad. Med.* 89: 38, 1923.
6. Eley, R. C., and Farber, S. Hypoplasia of the mandible (micrognathia) as a cause of cyanotic attacks in the newly born infant: Report of four cases. *Am. J. Dis. Child.* 39: 1167, 1930.

7. Denny, A., and Kalantarian, B. Mandibular distraction in neonates: A strategy to avoid tracheostomy. *Plast. Reconstr. Surg.* 109: 896, 2002.
8. Monasterio, F. O., Drucker, M., Molina, F., and Ysunza, A. Distraction osteogenesis in Pierre Robin sequence and related respiratory problems in children. *J. Craniofac. Surg.* 13: 79, 2002.
9. Losken, A., Williams, J. K., Burstein, F. D., et al. Outcome analysis for correction of single suture craniosynostosis using resorbable fixation. *J. Craniofac. Surg.* 12: 451, 2001.
10. Burstein, F. D., Williams, J. K., Hudgins, R. H., et al. Single-stage craniofacial distraction using resorbable devices. *J. Craniofac. Surg.* 13: 776, 2002.
11. Daskalogiannakis, J., Ross, R. B., and Tompson, B. D. The mandibular catch up controversy in Pierre Robin sequence. *Am. J. Dentofac. Orthop.* 120: 280, 2001.
12. Van den Elzen, A. P., Semmekrot, B. A., Bongers, E. M., et al. Diagnosis and treatment of the Pierre Robin sequence: Results of a retrospective study and review of the literature. *Eur. J. Pediatr.* 160: 47, 2001.
13. Marques, I. L., de Sousa, T. V., Carneiro, A. F., et al. Clinical experience with infants with Robin sequence: A prospective study. *Cleft Palate Craniofac. J.* 38: 171, 2001.
14. Cruz, M. J., Kerschner, J. E., Beste, D. J., et al. Pierre Robin sequence: Secondary respiratory difficulties and intrinsic feeding abnormalities. *Laryngoscope* 109: 1632, 1999.
15. Caouette-Laberge, L., Bayet, B., and Larocque, Y. The Pierre Robin sequence: Review of 125 cases and evolution of treatment modalities. *Plast. Reconstr. Surg.* 93: 934, 1994.
16. Wagner, S., Rayatt, S. S., Tatman, A. J., Gornall, P., and Slator, R. Management of infants with Pierre Robin sequence. *Cleft Palate Craniofac. J.* 40: 180, 2003.
17. Kirschner, R. E., Low, D. W., Randall, P., et al. Surgical management in Pierre Robin sequence: Is there a role for tongue lip adhesion? *Cleft Palate Craniofac. J.* 40: 13, 2003.
18. Denny, A. D., Talisman, R., Hanson, P. R., and Recinos, R. F. Mandibular distraction in very young patients to correct airway obstruction. *Plast. Reconstr. Surg.* 108: 302, 2001.
19. Sidman, J. D., Sampson, D., and Templeton, B. Distraction osteogenesis of the mandible for airway obstruction in children. *Laryngoscope* 111: 1137, 2001.
20. Villani, S., Brevi, B., and Sesenna, E. Distraction osteogenesis in a newborn infant with Pierre Robin sequence. *Mund. Kiefer. Gesichtschir.* 6: 197, 2002.
21. Judge, B., Hamlar, D., and Rimell, F. L. Mandibular distraction osteogenesis in a neonate. *Arch. Otolaryngol. Head Neck Surg.* 125: 1029, 1999.
22. Cohen, R. C., Rutrick, R. E., and Burstein, F. D. Distraction osteogenesis of the human craniofacial skeleton: Initial experience with a new distraction system. *J. Craniofac. Surg.* 6: 368, 1995.